

Difference Between Maxillary Central and Lateral Incisor

www.differencebetween.com

Key Difference - Maxillary Central vs Lateral Incisor

Dental [anatomy and physiology](#) have been studied over the years to elucidate the structure and functions of different types of [teeth](#), especially in humans. The maxillary teeth are the teeth present in the upper jaw that are comprised of four types: Incisors, Canines, Premolars, and [Molars](#). Incisors are further divided into the maxillary central incisors and maxillary lateral incisors depending on their shape and structure. They are characterized based on several aspects: labial aspect, mesial aspect, distal aspect and incisal aspect. Maxillary central incisors are central incisors that erupt during the age of seven to eight. Maxillary lateral incisors are situated laterally in the upper jaw and they emerge at the age of eight to nine. The **key difference** apart from the various structural differences shown by maxillary central and lateral incisors is their time of erupting. **Maxillary central incisors erupt first whereas maxillary lateral incisors erupt later.**

What is a Maxillary Central?

Maxillary central incisors are situated in the center of the maxilla, and two central incisors are situated on either side of the mid line. The main function of maxillary central incisors is to cut the food during mastication of [mechanical digestion](#) to form the food bolus.

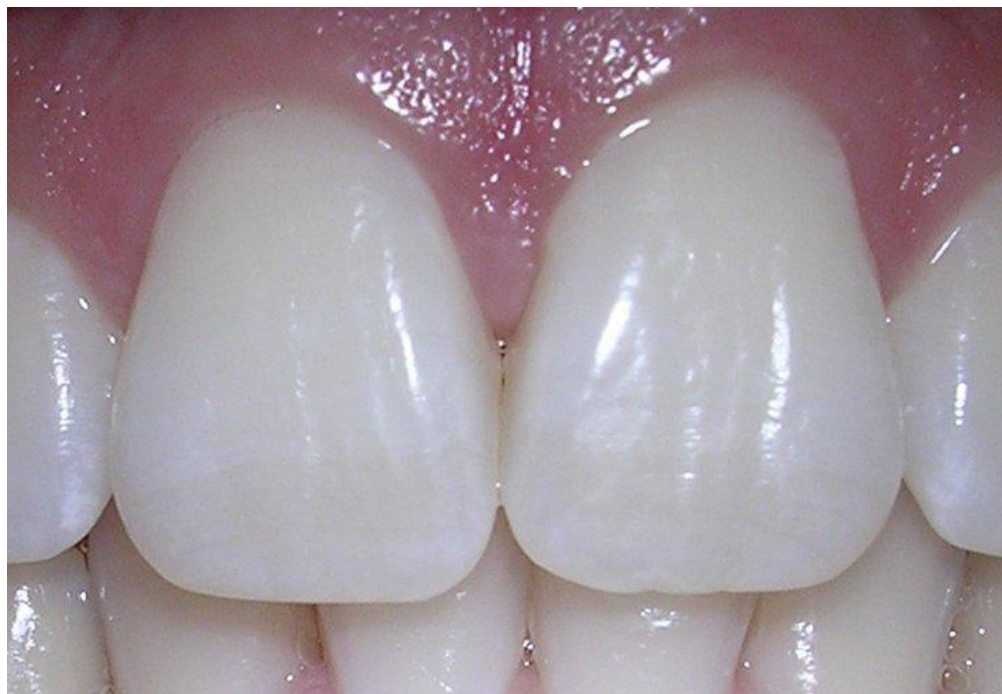

Figure 01: Maxillary Central Incisor

The anatomy and physiology of the maxillary central can be explained in different aspects as follows;

1.Labial Aspect

The average length of the crown will be 10 -11mm from the highest (cervical line) to the lowest point (incisal edge). The mesial outline of the crown is convex whereas the distal outline is more convex. The extent of the curvature depends mostly on the typical form of the tooth.

2.Mesial aspect

The crown is wedge-shaped or triangular in shape. The root of the maxillary central incisor is cone-shaped. The apex of the root is bluntly round shaped.

3.Distal Aspect

The distal and mesial outline cannot be distinguished well in maxillary central incisors. The curvature of the cervical line is less in extent from the distal aspect in comparison with the mesial aspect.

4.Incisal Aspect

The crown of the maxillary central appears to be bulkier from the incisal aspect. The crown conforms to a triangular outline reflected by the outline of the root cross section.

What is a Lateral Incisor?

Maxillary lateral incisors are situated on either side of the central maxillary incisors and they function to cut the food during the process of mastication. They are similar in shape to central maxillary incisors but are shorter and are narrower than the maxillary central incisors.

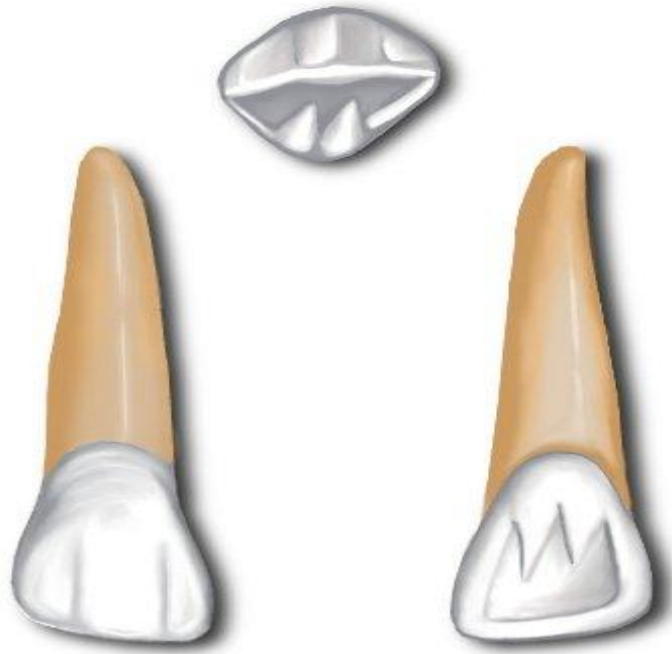


Figure 02: Maxillary Lateral Incisors

Minute differences in different aspects of dental anatomy can be observed in maxillary lateral incisors.

1.Labial aspect

The mesial and the distal margins are marked from the lingual aspect. The cingulum is prominent. The developmental grooves are present and join the cingulum.

2.Mesial aspect

In the mesial aspect of the maxillary lateral, the crown is shorter, and the root is longer. The curvature is less and the incisal ridge is heavily developed. This gives a thick appearance to the maxillary central. The root appears as a tapered cone, and its apical end is blunt and round shaped.

3.Distal aspect

A developmental groove can be found extending of the root part of the maxillary central. The width of the crown appears thicker.

4.Incisal aspect

The incisal aspect of the maxillary lateral incisors resembles mostly the maxillary central and the canine. The cingulum is larger, and the incisal ridge is prominent.

What are the Similarities Between Maxillary Central and Lateral Incisor?

- Both are situated in the upper jaw.
- Both are arising from the maxillary bone.
- Both functions in cutting food during mastication to form the food bolus.
- Both types of teeth can be characterized based on different aspects such as mesial, distal, incisal.

What is the Difference Between Maxillary Central and Lateral Incisor?

Maxillary Central vs Lateral Incisor	
Maxillary central incisors are central incisors situated on either side of the median line that erupts during the age of seven to eight.	Maxillary lateral incisors are incisors situated on either side of the central incisors that erupts during the age of eight to nine.
Crown	
Crown of the maxillary central incisor is larger and wider.	Crown of the maxillary lateral incisor is smaller and narrow.
Root	
Root is shorter in maxillary central incisor.	Root is longer in maxillary lateral incisor.
Labial Aspect	
Relatively flat	More rounded in shape
Mesial Aspect	
Straight	Slightly rounded
Distal Aspect	
Round	Highly rounded
Incisal Aspect	
Sharp	Slightly rounded

Summary - Maxillary Central vs Lateral Incisor

Teeth play an important role in the mechanical digestion of food in the process known as mastication. Incisors are important in cutting food. The maxillary incisors are the incisors situated in the upper jaw, and there are four maxillary incisors – two central maxillary incisors and two lateral incisors. Maxillary central incisors develop first followed by lateral incisors. The crown of maxillary central incisors is wider and short in comparison with the maxillary lateral incisors which have long and narrower crown. They differ in different aspects such as lingual aspects, mesial aspects, distal aspects and incisal aspects. However, the difference between maxillary central and lateral incisors is in their time of erupting.

Reference:

- 1.“The Permanent Maxillary Incisors (Dental Anatomy, Physiology, and Occlusion) Part 1.” Whatwhenhow RSS, what-when-how.com/dental-anatomy-physiology-and-occlusion/the-permanent-maxillary-incisors-dental-anatomy-physiology-and-occlusion-part-1/.
- 2.“The Permanent Maxillary Incisors (Dental Anatomy, Physiology, and Occlusion) Part 2.” Whatwhenhow RSS, what-when-how.com/dental-anatomy-physiology-and-occlusion/the-permanent-maxillary-incisors-dental-anatomy-physiology-and-occlusion-part-2/.
- 3.“The Permanent Maxillary Incisors (Dental Anatomy, Physiology, and Occlusion) Part 3.” Whatwhenhow RSS, what-when-how.com/dental-anatomy-physiology-and-occlusion/the-permanent-maxillary-incisors-dental-anatomy-physiology-and-occlusion-part-3/.

Image Courtesy:

- 1.'06-10-06centralincisors' By dozenist - Own work, [\(CC BY-SA 3.0\)](#) via [Commons Wikimedia](#)
- 2.'Maxillary lateral incisor' By Ανώνυμος Βικιπαίδιστής - Own work, [\(CC BY 3.0\)](#) via [Commons Wikimedia](#)

How to Cite this Article?

APA: Difference Between Maxillary Central and Lateral Incisor.(2017 November 15). Retrieved (date), from <http://differencebetween.com/difference-between-maxillary-central-and-vs-lateral-incisor/>

MLA: "Difference Between Maxillary Central and Lateral Incisor" Difference Between.Com. 15 November 2017. Web.

Chicago: “Difference Between Maxillary Central and Lateral Incisor.” Difference Between.Com. <http://differencebetween.com/difference-between-maxillary-central-and-vs-lateral-incisor/> accessed (accessed [date]).



Copyright © 2010-2017 Difference Between. All rights reserved