

Difference Between Cyanotic and Acyanotic Congenital Heart Defects

www.differencebetween.com

Key Difference – Cyanotic vs Acyanotic Congenital Heart Defects

The birth of a perfectly normal baby is an absolute miracle which has lost its awe-inspiring nature because it happens so frequently. Many things can go wrong during the formation and the growth of a **fetus**. The cardiac defects that we are going to discuss in this article are also such disorders that are due to the malformation of certain components of the heart during the embryological stage. As their names suggest, **cyanosis** is observed only in the cyanotic congenital heart defects and not in their acyanotic counterparts. But the key difference between cyanotic and acyanotic congenital heart defects is that **the movement of blood is from the right side to the left side of in the cyanotic defects whereas the movement of blood is from the left side to the right side of the heart in the acyanotic diseases.**

What are Cyanotic Congenital Heart Defects?

Cyanotic congenital heart defects are due to the defects in the **circulatory system** present at birth that give a bluish tint to the skin which is known as cyanosis. Cyanosis is a result of the shunting of blood from the right side to the left side of the heart, decreasing the oxygen saturation and increasing the content of **deoxygenated hemoglobin** in the blood.

The following pathological conditions are included in this group

- Fallot's tetralogy
- Transposition of the great **arteries**
- Tricuspid atresia

Fallot's Tetralogy

The four cardinal features of Fallot's tetralogy are,

- Ventricular septal defect

- Subpulmonary stenosis
- Overriding aorta
- Right ventricular hypertrophy

These defects are due to the anterosuperior displacement of the infundibular septum during the embryological stage.

Morphological Features

The heart is usually enlarged and has a characteristic boot shape.

Clinical Features

Patients with TOF can survive into the adulthood even without proper treatments. Subpulmonary stenosis is the determining factor of the severity of symptoms. In case of a mild subpulmonary stenosis, clinical picture will be similar to that of an isolated VSD. Only a severe degree of stenosis can give rise to the cyanotic form of the disease. The severity of subpulmonary stenosis and hypoplasticity of pulmonary arteries are directly proportional.

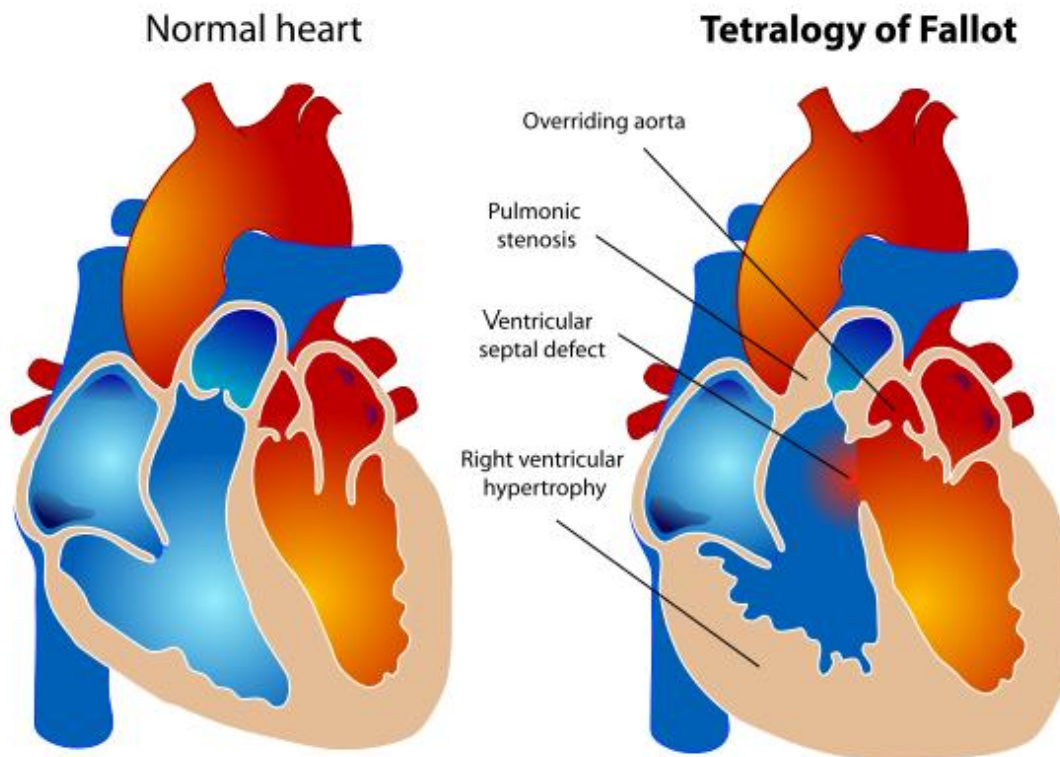


Figure 01: Fallot's Tetralogy

Transposition of the Great Arteries

The malformation of the truncal and aortopulmonary septa is the embryological basis of this condition. Ventriculoarterial discordance is the prominent pathological feature.

Prognosis of the disease depends on three main factors

- Degree of the mixing of blood
- Degree of **hypoxia**
- Ability of the right ventricle to maintain the systemic circulation

With the growth of the child, the persistent workload on the right ventricle which acts as the systemic ventricle results in its **hypertrophy**. Concurrently, left ventricle undergoes atrophy because of the diminished resistance of the pulmonary circulation.

Tricuspid Atresia

The complete occlusion of the orifice of the tricuspid valve is called the tricuspid atresia. The asymmetrical separation of the AV canal is the underlying embryological defect. Widened mitral valve and right ventricular hypoplasia are the prominent morphological features. The prognosis is usually bad, and the patient dies within the first five years of life.

What are Acyanotic Congenital Heart Defects?

Acyanotic congenital heart defects are also due to the inborn structural defects in the circulatory system. But cyanosis is not observed in this group of diseases because the adequate concentration of deoxygenated hemoglobin is not produced due to various reasons.

The following conditions are considered as acyanotic congenital heart defects

- Obstructive lesions- pulmonary stenosis, aortic stenosis, Coarctation of the aorta
- Atrial septal defect (ASD)
- Ventricular septal defect

- Patent ductus arteriosus
- Pulmonary stenosis
- Atrioventricular septal defect

ASD

These are due to the malformation of the septum that separates the two atria. Three main forms of ASD have been described.

- Ostium primum
- Ostium Secundum
- Sinus venosus defect

Clinical Features

Most of the patients with ASD usually remain asymptomatic. The following signs can be elicited during the examination of the cardiovascular system.

- Systolic ejection murmur
- Chest X-ray shows cardiomegaly with prominent pulmonary vasculature and a prominent PA bulb.
- Cardiac catheterization may show an increase in the oxygen saturation between SVC and right atrium during mixing.

The defect should be corrected through surgical intervention before 4-5 years of age.

VSD

These are the commonest variety of congenital heart diseases and are classified into three groups according to the region of the ventricular septum that is having the malformation.

- Membranous defect – defect is in the membranous septum
- Muscular defect – muscular and apical portions of the septum are affected
- Infundibular defect -defect lies just underneath the pulmonary valve

In a vast majority of the cases, the defect regresses spontaneously. Intervention is required only if the patient shows signs and symptoms of cardiac failure.

The clinical picture is similar to that of ASD. The auscultation of a holo systolic murmur just below the left sternocostal edge indicates the possibility of a VSD. Chest X rays can show cardiomegaly and prominent cardiac vasculature. Symptoms of cardiac failure appear only in the patients with a large defect in the septum.

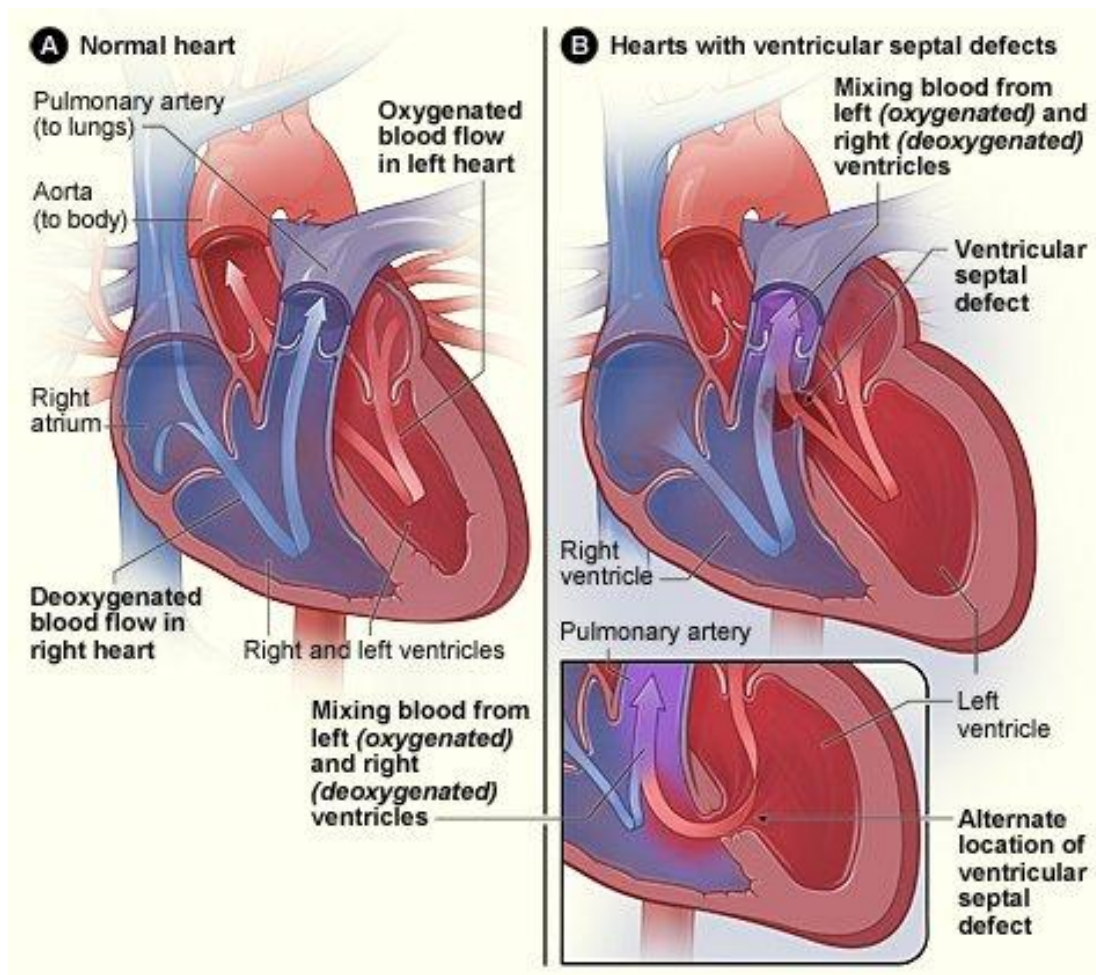


Figure 02: VSD

Patent Ductus Arteriosus

The fetal ductus arteriosus is present in the fetal circulation in order to facilitate the diversion of blood from the pulmonary artery to the descending aorta, and this tract usually closes within few weeks after the birth. Its persistence during the infancy is termed as the patent ductus arteriosus.

Coarctation of the Aorta

The narrowing of the aorta at the site from where the ductus arteriosus emanates is known as the coarctation of the aorta. It usually occurs in conjunction with other cardiac defects such as a bicuspid aortic valve. Patients become symptomatic during the first three months of life.

The clinical presentation includes,

- Systemic hypoperfusion
- Metabolic acidosis
- Congestive cardiac failure

What are the similarities between Cyanotic and Acyanotic Congenital Heart Defects

- Cyanotic and acyanotic congenital heart defects are due to the inborn defects in various structural components of the heart.

What is the difference between Cyanotic and Acyanotic Congenital Heart Defects?

Cyanotic vs Acyanotic Congenital Heart Defects	
Direction of the Blood Flow	
Blood moves from right side to the left side of the heart.	Blood moves from left side to the right side of the heart.
Condition of Blood	
The blood moving to the left side is deoxygenated.	The blood moving to the right side is oxygenated.
Cyanosis	
Cyanosis is present.	Cyanosis is absent.

Summary – Cyanotic vs Acyanotic Congenital Heart Defects

Cyanotic and acyanotic congenital heart defects are due to the inborn structural defects of the heart. In the cyanotic form of the defects, the movement of blood is from the right side to the left side of the heart. The blood moves from left side to the right side in the acyanotic group of defects. This is the key difference between cyanotic and acyanotic heart defects.

References:

1. Kumar, Vinay, Stanley Leonard Robbins, Ramzi S. Cotran, Abul K. Abbas, and Nelson Fausto. Robbins and Cotran pathologic basis of disease. 9th ed. Philadelphia, Pa: Elsevier Saunders, 2010. Print.

Image Courtesy:

1. “Tetralogy of Fallot” By Mariana Ruiz LadyofHats – (Public Domain) via [Commons Wikimedia](#)
2. “VSD image” By [National Heart Lung and Blood Institute](#) – (Public Domain) via [Commons Wikimedia](#)

How to Cite this Article?

APA: Difference Between Cyanotic and Acyanotic Congenital Heart Defects. (2017, September 20). Retrieved (date), from <http://differencebetween.com/difference-between-cyanotic-and-vs-acyanotic-congenital-heart-defects/>

MLA: "Difference Between Cyanotic and Acyanotic Congenital Heart Defects" *Difference Between.Com*. 20 September 2017. Web.

Chicago: “Difference Between Cyanotic and Acyanotic Congenital Heart Defects.” *Difference Between.Com*. <http://differencebetween.com/difference-between-cyanotic-and-vs-acyanotic-congenital-heart-defects/> accessed (accessed [date]).



Copyright © 2010-2017 Difference Between. All rights reserved