

Difference Between Cyst and Polyp

www.differencebetween.com

Key Difference – Cyst vs Polyp

A polyp is a mass that grows above a mucosal surface to form a macroscopically visible structure. A cyst is a nodule consisting of an **epithelial** lined cavity filled with a fluid or semi-solid material. The key difference cyst and polyp is that **cysts have a fluid filled cavity while polyps do not have fluid filled cavities**. It is important to know the difference between cyst and polyp clearly in order to manage and treat these conditions.

What is a Polyp?

A mass that grows above a mucosal surface to form a macroscopically visible structure is known as a polyp. These are usually attached to the mucosa by a distinct stalk.

In most occasions, polyps are benign tumors, but there can be malignant polyps as well. Inflammatory polyps such as those seen in the nasal mucosa are nonneoplastic.

Colorectal Polyps

An abnormal tissue growth which protrudes from the colonic mucosa is called a colonic polyp. These polyps can be either single or multiple, and they can be found in several forms such as

- Pedunculated polyps
- Flat polyps
- Sessile polyps

The diameter of a polyp may vary from few millimeters to several centimeters.

Colorectal polyps have been categorized into various categories such as **adenoma**, hamartoma and etc. according to their histological features.

Pathological conditions associated with the formation of colorectal polyps:

1. Sporadic Adenomas

Adenoma is the precursor lesion of colonic cancers. Initially, they appear as benign tumors but can become malignant with the occurrence of dysplastic changes.

The risk of malignant transformation is high if the colonic polyp,

- Is more than 1.5 cm in diameter,
- Is multiple, sessile or flat,
- Has severe dysplasia with villous architecture and associated squamous metaplasia.

If the risk malignant transformation is high, colonoscopy is carried out to remove the tumors from the gut. Continuous surveillance is necessary even after their removal.

Rectal bleeding is the most commonly seen clinical feature of polyps in the rectum and sigmoid colon. Proximal lesions are usually symptomless.

2. Sessile Serrated Adenoma

Benign hyperplastic polyps (HPS), traditional serrated adenomas (TSA) and premalignant sessile serrated adenomas(SSA) fall under this category. These lesions differ from the others due to the sawtooth appearance of the epithelial layer. Endoscopic resection of SSAs and TSA s is recommended.

3. Colorectal Carcinoma

Colorectal carcinoma is the third commonest cancer worldwide.

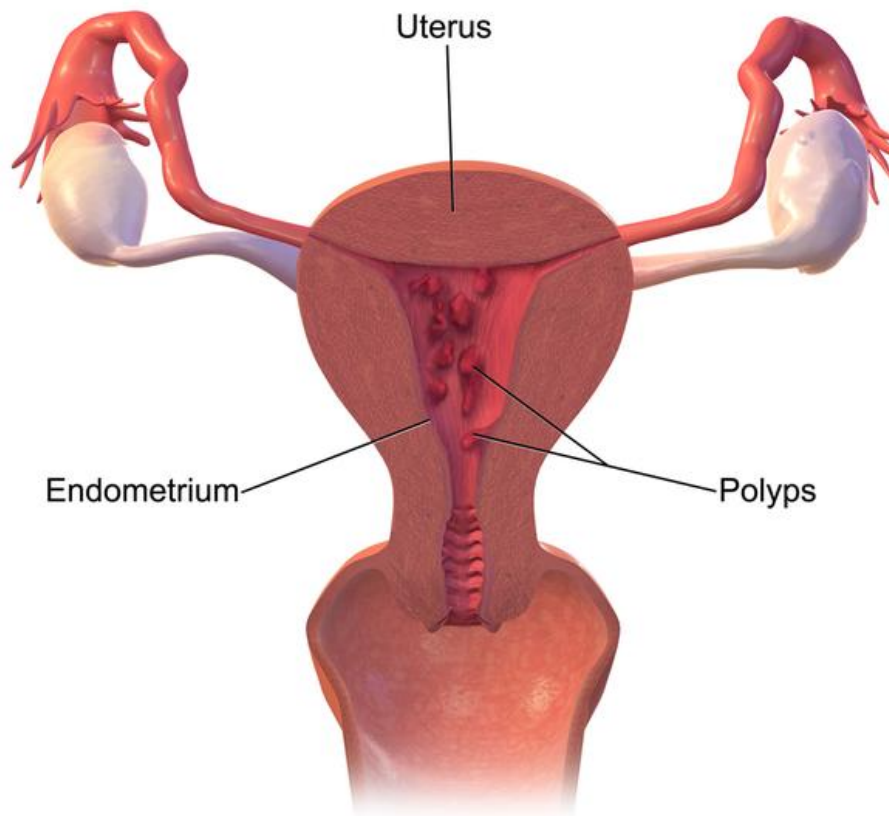
Clinical features of the disease are,

- Loose stools
- Rectal bleeding
- Symptoms of [anemia](#)
- Tenesmus
- Palpable rectal or abdominal mass

The following investigations are done to exclude the possibility of a colorectal carcinoma

- Colonoscopy -the gold standard
 - Endoanal ultrasound and pelvic MRI
 - Double contrast barium enema

A multidisciplinary team involvement is necessary for the management of the disease. Surgical resection of the affected region of the **intestines** is carried out in most of the patients. The surgical procedure varies according to the site of cancer, and the disease prognosis depends on the staging and the presence of metastasis.



Uterine Polyps

Figure 01: Uterine Polyps

Gall Bladder Polyps

Gall bladder polyp is a common finding among patients who are referred to hepatobiliary ultrasonography. These polyps are inflammatory and contain

cholesterol deposits. Most of them are small and benign. There can be malignant ones as well. If the size of polyp is more than 10cm, they can be malignant. Cholecystectomy is the recommended treatment for these.

Gastric Polyps

This disease is relatively rare and asymptomatic most of the time. Larger lesions may result in hematemesis or anemia. Diagnosis of the lesion can be made with endoscopy. Polypectomy can be performed depending on the histology of the polyp. Surgical intervention is required when large or multiple polyps are present.

Nasal Polyps

These polyps are round, smooth, soft, semi-translucent, pale structures that are attached to the nasal mucosa by a narrow stalk. They usually occur in patients with [allergic or vasomotor rhinitis](#). Mast cells, [eosinophils](#), and mononuclear cells are found in large numbers within them. Nasal polyps may cause nasal obstruction, loss of taste and smell and mouth breathing. Intranasal steroids are used in treating this condition.

What is a Cyst?

A nodule consisting of an epithelial lined cavity filled with fluid or semi-solid material is called a cyst. Most cysts that we come across are translucent, lined by a gray, glistening, smooth membrane and filled with a clear fluid. Cysts occur due to various pathological reasons in several organs like liver, kidney, and lungs. Some of the cysts that may appear in the human body are,

- Hydatid cyst
- Cystic diseases of the kidney
- Fibrocystic disease of the liver
- Lung cysts
- Biliary cysts
- Baker's cyst
- Sebaceous cyst
- Pilar cyst

Hydatid Cysts

Hydatid cysts are formed in the hydatid disease where the human becomes an intermediate host of the dog tapeworm, *Echinococcus granulosus*. The adult worm lives in the intestine of domestic and wild canines. Humans get infected from direct contact with dogs or from food or water contaminated with dog feces. After ingestion, the worm exocyst penetrates the gut wall and enters the liver and other organs via blood. A thick walled, slow growing cyst is formed. Inside this cyst, further development of larval stages of the parasite takes place. The liver is the commonest organ affected by this condition. The most frequently observed clinical manifestations are,

- **Jaundice** (due to pressure on bile duct)
- Abdominal pain
- Fever associated with eosinophilia
- Expectoration (due to cyst rupturing into bronchus)
- Chronic pulmonary abscess
- Focal seizures (due to cyst present in brain)
- Lumbar pain and hematuria

Investigations may show peripheral eosinophilia and positive hydatid complement fixation test. Calcification of the outer coat of the cyst can be observed in a plain abdominal X-ray.

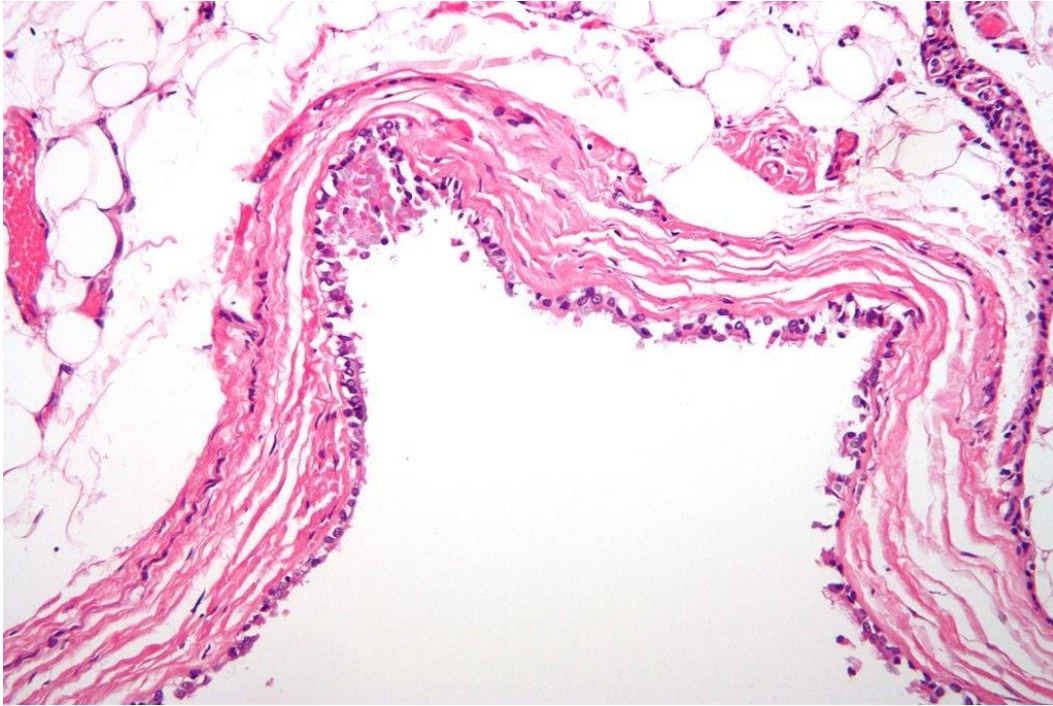


Figure 02: Micrograph of a mediastinal bronchogenic cyst

Management

- Albendazole 10mg/kg can reduce the size of the cyst.
- Puncture, aspiration, injection, re-aspiration(PAIR) can be carried out
- Fine- needle aspiration is done with ultrasound guidance

Cystic Diseases of the Kidney

Cystic diseases of the kidney are hereditary, developmental or acquired disorders. Several forms of renal cystic diseases are listed below.

- Adult polycystic disease
- Childhood (autosomal recessive) polycystic disease
- Solitary cysts
- Medullary diseases with cysts

Fibrocystic Diseases of Liver

These disorders can give rise to hepatic cysts or fibrosis. Polycystic disease of the liver occurs as a part of the polycystic disease of the kidney. Hepatic fibrocystic diseases are usually asymptomatic but occasionally can cause abdominal pain and distention.

What is the difference between Cyst and Polyp?

Cyst vs Polyp	
A cyst is a nodule consisting of an epithelial lined cavity filled with fluid or semi-solid material.	A polyp is a mass that grows above a mucosal surface to form a macroscopically visible structure.
Fluid Filled Cavities	
Cysts have a fluid filled cavity.	Polyps do not have fluid filled cavities.

Summary – Cyst and Polyp

As discussed at the beginning, a cyst is a nodule consisting of an epithelial lined cavity filled with fluid or semi-solid material and a polyp is a mass that grows above a mucosal surface to form a macroscopically visible structure. Thus, the difference between cyst and polyp is the presence of fluid filled cavities. Clearly identifying each condition is important in the management of the patient.

References:

1. Gawkrödger, David . Dermatology . N.p.: Churchill Livingstone, 2007. Print.
2. Kumar, Parveen J., and Michael L. Clark. Kumar & Clark clinical medicine. Edinburgh: W.B. Saunders, 2009. Print.
3. Kumar, Vinay, Stanley Leonard Robbins, Ramzi S. Cotran, Abul K. Abbas, and Nelson Fausto. Robbins and Cotran pathologic basis of disease. 9th ed. Philadelphia, Pa: Elsevier Saunders, 2010. Print

Image Courtesy:

1. “Bronchogenic cyst high mag” By Nephron – Own work (CC BY-SA 3.0) via [Commons Wikimedia](#)
2. “Uterine Polyps” By BruceBlaus – Own work (CC BY-SA 4.0) via [Commons Wikimedia](#)

How to Cite this Article?

APA: Difference Between Cyst and Polyp. (2017, July 28). Retrieved (date), from <http://differencebetween.com/difference-between-cyst-and-vs-polyp/>

MLA: "Difference Between Cyst and Polyp" *Difference Between.Com*. 28 July 2017. Web.

Chicago: " Difference Between Cyst and Polyp." *Difference Between.Com*. <http://differencebetween.com/difference-between-cyst-and-vs-polyp/> accessed (accessed [date]).



Copyright © 2010-2017 Difference Between. All rights reserved.